

CHEMOTHERAPY INDUCED CHANGES IN WILMS TUMOR: AN INSTITUTIONAL EXPERIENCEKarthik Vijay¹, Appu Thomas², Ginil Kumar³**HOW TO CITE THIS ARTICLE:**

Karthik Vijay, Appu Thomas, Ginil Kumar. "Chemotherapy Induced Changes in Wilms Tumor: An Institutional Experience". Journal of Evolution of Medical and Dental Sciences 2014; Vol. 3, Issue 17, April 28; Page: 4666-4670, DOI: 10.14260/jemds/2014/2493

ABSTRACT: Title: Chemotherapy induced changes in Wilms tumor: An institutional experience 20 cases of wilms tumor were treated with SIOP protocol using preoperative chemotherapy with vincristine and actinomycin D, the response of the tumor by decrease in size was assessed by imaging and histopathological response was also assessed. 10 cases were of wilms were treated using the NWTS protocol with upfront nephrectomy and used as controls. Gross size reduction was seen with SIOP protocol and significant response of epithelial and stromal elements were noted, as well as blastemal nodules. Diffuse anaplasia did not respond to chemotherapy. This evaluation helps to define the susceptibility of different elements in wilms tumor to chemotherapy.

KEYWORDS: Wilms tumor, NWTS, SIOP.

INTRODUCTION: With the availability of several protocols in the management of Wilms' tumor, there is dilemma in the minds of the treating doctors as to whether the child should receive upfront chemotherapy or should be operated upon primarily. The two major groups in wilms tumor study are NWTS (National Wilms Tumor Study Group) which follows the upfront surgery principle and the SIOP (International Society of Pediatric Oncology) which follows the upfront chemotherapy principle in all stages of the disease. Our purpose of the study was to analyse response of Wilms tumor on imaging and histologically following upfront chemotherapy.

MATERIALS AND METHODS: 20 cases of Wilms tumor from 2002-2012, who were given preoperative chemotherapy with vincristine (V) and actinomycin D (A) were studied (SIOP). Change in the size of tumor on imaging and histopathology of the nephrectomy specimen in response to chemotherapy were assessed. 10 patients were used as controls who did not receive chemotherapy (NWTS) but under-went upfront radical nephrectomy. Tumors were staged according to the SIOP and NWTS staging systems. SIOP chemotherapy protocol was followed. Reimaging done after 3 weeks of chemotherapy with ultrasound. Surgery (open transperitoneal Radical nephrectomy) was done 4 weeks after chemotherapy. SIOP protocol (preoperative): Table 1.

RESULTS: Tumors treated with SIOP protocol were mainly stage II (see figure 4), while those treated with NWTS protocol were in stage I (figure 5). Mean age of the children was 4 years (figure 1). Most were females (figure 2) and right side tumor were more (figure 3). Preoperative chemotherapy with vincristine and actinomycin D brought about gross reduction in the size of the tumor (table 2).

Average size of the tumor preop was 8 cm. Post chemotherapy average size of the tumor was 4 cm. Histologically epithelial and stromal and mixed elements showed good response (Table 3).

Complete necrosis seen in 3 cases. Blastemal nodules were also reduced in size. Glomerular and tubular components were unaffected. Vascular changes: thrombosis, necrosis and acute

ORIGINAL ARTICLE

inflammation were present Anaplasia (1): diffuse, did not respond to Chemotherapy. 1 case of wilms treated with NWTS protocol had intraoperative tumor spillage .1 patient treated as wilms with chemotherapy was reported as congenital mesoblastic nephroma in the histopathology report post nephrectomy.

DISCUSSION: Great strides have been made in the treatment of Wilms' tumor. Both NWTS and SIOP have shown equal efficacy in clinical outcome.

NWTS recommends upfront surgery – nephrectomy. A trans-abdominal, trans-peritoneal incision is recommended to permit the inspection of sites of involvement and to facilitate the biopsy of suspicious sites.¹ Pre-operative chemotherapy as per NWTS 5 studies is indicated when Wilms' tumor occurs in a solitary kidney, when it occurs in horseshoe kidney, when there is tumor thrombus in the inferior vena cava above the level of the hepatic veins, and when the child presents with respiratory distress due to extensive pulmonary metastases.

SIOP recommends upfront chemotherapy to all patients, including the stage 1 Wilms' tumor, except for children with less than 6 months of age.² Benefit of pre-chemotherapy lies in reduction of tumor volume and down-staging the tumor and thus reducing the chances of intra-operative tumor spillage.³

Histologic classification is a major issue for debate since the time these study groups have started. In NWTS, upfront nephrectomy provides for the entire kidney for histological evaluation and accurate risk stratification based on presence or absence of anaplasia, classifying as favorable and unfavorable. In SIOP to a certain extent, the histology is altered with chemotherapy with the necrosis of the tumor cells; however, the anaplastic features of the tumor are notable, which are important for risk stratification and do not regress with pre-operative chemotherapy.

Advantage of preoperative chemotherapy is that response to treatment may provide a valuable prognostic indicator as well.³ Chemotherapy thereby plays an undisputed role in management of Wilms' tumor.

CONCLUSION: Preoperative chemotherapy brings about down-sizing and staging of the tumor and reduces the risk of intra operative tumor rupture and complications. Histologically, Epithelial and stromal elements show a better response than blastemal components. Anaplasia (diffuse) do not respond to chemotherapy. Disadvantage of SIOP was treatment of non wilms or benign tumor with chemotherapy.

Abbreviations:

1. NWTS – national wilms tumor study group
2. SIOP – international society of paediatric oncology

Formulae: Vincristine: <10kg: 0.05 m/kg/dose IV q week
>10kg: 1.5-2mg/m square/dose
Actinomycin D: 15 microgm/kg IV qd x5days

ORIGINAL ARTICLE

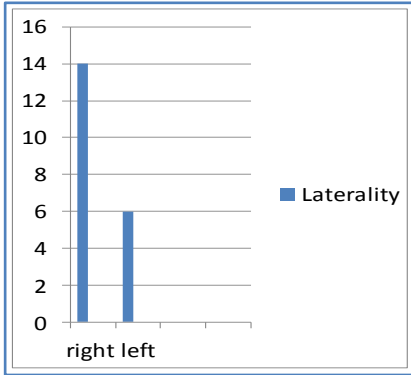


Figure 1: Age

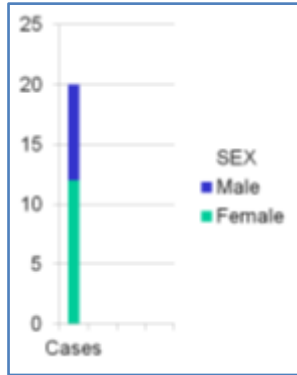


Figure 2

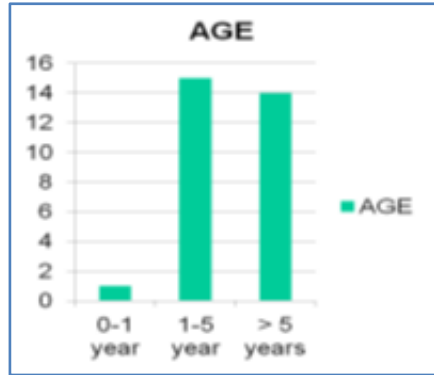


Figure 3

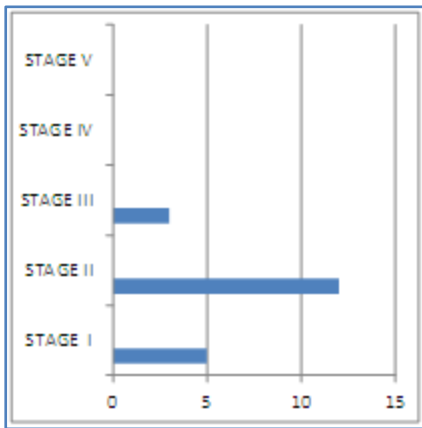


Figure 4: Cases

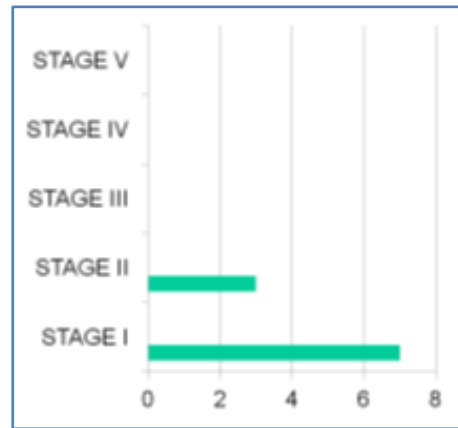


Figure 5: Controls

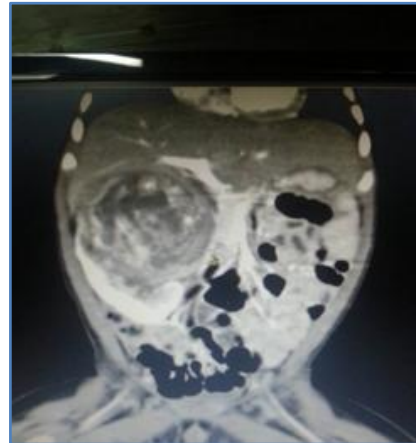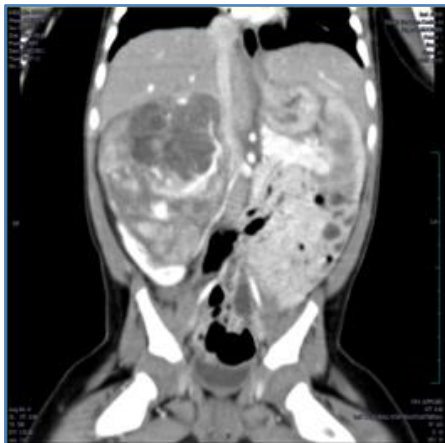


Figure 6: Right sided wilms tumor pre chemotherapy

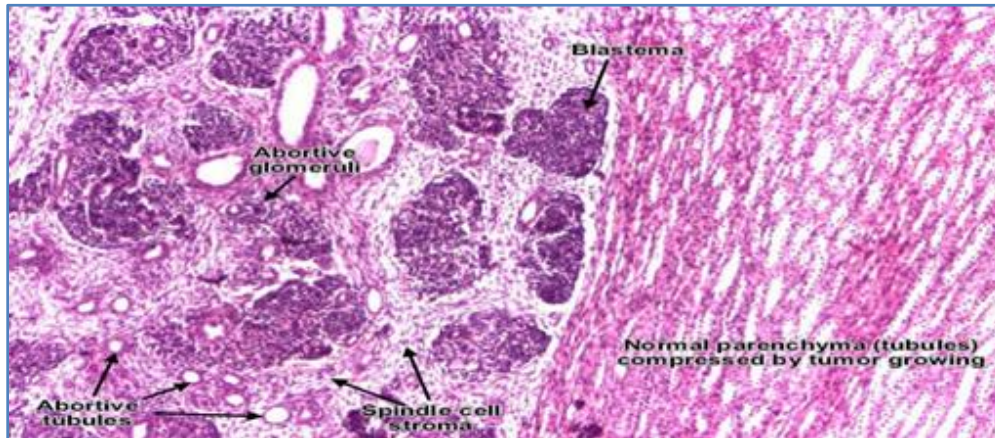


Figure 7: Triphasic pattern of wilms tumor: Blastema, epithelial and stromal elements

Clinical staging	Chemotherapy	
Localized	4 weeks of DAM/VCR	Surgical staging
Metastatic	6 weeks of DAM/VCR/EPI	Histological diagnosis

Table 1: Pre-Operative chemotherapy

DAM-Dactinomycin; VCR-Vincristine; EPI-Epirubicin

cases	Pre chemo average size (cm)	Post chemo average size (cm)	P. value
20	8 cm	4 cm	<0.001

Table 2: Pre and Post chemotherapy size change

Statistical analysis: paired T square test

Histology	Number	Pre chemo avg size (cm)	Post chemo avg size (cm)
Mixed	10	8cm	4cm
Necrosis	3	7cm	4cm
Epithelial and Stromal	1	8cm	4.5cm
Blastemal	4	9cm	6cm
Anaplastic And other(CMN)	1 1	8cm	8cm

Table 3: Histology result

ORIGINAL ARTICLE

REFERENCES:

1. Sushmita Bhagat et al. Management of Wilms' tumor: NWTS vs. SIOP. Indian Assoc Pediatr Surg J. 2009 Jan-Mar; 14(1): 6-14.
2. Guarda et al. Chemotherapy-induced histologic changes in Wilms tumors. Paediatr Patho 1984; 2 (2):197-20.
3. Ng YY et al. Wilms' tumour: pre- and post-chemotherapy CT appearances. Clin Radiol 1991 Apr; 43 (4):255-9.
4. John A Kalapuraka et al. Management of Wilms' tumour: current practice and future goals. The Lancet Oncology, Volume 5, Issue 1, Pages 37 - 46, January 2004.

AUTHORS:

1. Karthik Vijay
2. Appu Thomas
3. Ginil Kumar

PARTICULARS OF CONTRIBUTORS:

1. Resident, Department of Urology, Amrita Institute of Medical Sciences.
2. HOD, Department of Urology, Amrita Institute of Medical Sciences.
3. Professor, Department of Urology, Amrita Institute of Medical Sciences.

NAME ADDRESS EMAIL ID OF THE CORRESPONDING AUTHOR:

Dr. Karthik Vijay,
Ashraya Hospital,
Chikmagalur - 577101.
E-mail:drkarthikvijay2000@gmail.com

Date of Submission: 20/03/2014.
Date of Peer Review: 21/03/2014.
Date of Acceptance: 14/04/2014.
Date of Publishing: 28/04/2014.